

The exceptional brain of Albert Einstein

Sandra F Witelson, Debra L Kigar, Thomas Harvey

In recent decades, there have been major advances in neuroscience at the behavioural and neural levels, but the long-standing issue of the neurobiological basis of variation in intelligence remains unresolved.¹ Around the turn of the 20th century, much attention was focused on anatomical correlates of intelligence through detailed necropsy case studies of the brains of outstanding people, such as mathematician Karl F Gauss or physician William Osler.^{2,3} By 1907, Spitzka⁴ had published an extensive monograph that summarised 137 case reports of notable men and women such as Bach and Descartes, and also presented one of the first group studies of nine scholars. Weight of the brain and patterns of gyral convolutions were usually examined.

This early work had several limitations. First, medical and cognitive status at the time of death were often not known. Second, normal comparison groups were not available, so that the results were mainly idiosyncratic observations. Quantitative measurement was usually limited to the weight of the whole brain, and even its relation to intelligence remained unresolved. For example, novelist Ivan Turgenev's brain weighed 2012 g,⁴ whereas the brain of author Anatole France was half the value (1017 g).⁵ Third, work was based on the assumption that intelligence was a unitary homogeneous ability—even though different people varied greatly in their area of cognitive excellence. (According to current theories of intelligence, there are independent spheres or modules of cognitive ability.⁶) Last, the studies had no a priori hypotheses as to the relation between structure and psychological function, since there was little knowledge about the cortical localisation of cognitive function.⁷

After the horrific events of World War II, issues related to the neurobiological substrate of intelligence were considered with great caution, and research in this area dwindled. The development of computerised imaging technologies has made it possible to obtain quantitative measurements of brain anatomy in vivo with magnetic resonance scanning, and renewed attention has been directed to the investigation of structure-function relations in the general population. The studies have varied greatly in their methodology, and, although the results are inconsistent, they do point to a low, but statistically significant, positive correlation between brain

volume and IQ scores.⁸ Further work is needed to reconcile these results with the inconsistent findings on brain weight in the earlier case reports. Brain volume and weight are not perfectly correlated, and imaging does not provide measures of brain weight.

The case of Albert Einstein

Resolving the neurobiological substrate of intelligence may be facilitated by the comparison of extreme cases with control groups within the framework of specific hypotheses. Albert Einstein is one of the intellectual giants of recorded history, and the preservation of his brain provides the possibility of an important case study. Since Einstein's death, there has been no report of the gross anatomy of his brain. Here we present the first such study.

Our investigation of Einstein's brain was guided theoretically on the basis of current information of cortical localisation of cognitive functions. The generation and manipulation of three-dimensional spatial images and the mathematical representation of concepts would appear to be essential cognitive processes in the development of Einstein's theory of relativity.⁹ Einstein's own description of his scientific thinking was that ". . . words do not seem to play any role", but there is "associative play" of "more or less clear images" of a "visual and muscular type".¹⁰ Visuospatial cognition,^{11,12} mathematical ideation,¹¹ and imagery of movement¹³ are mediated predominantly by right and left posterior parietal regions. We hypothesised that the parietal lobes in particular might show anatomical differences between Einstein's brain and the brains of controls.

Preservation of Einstein's brain

Einstein died from a ruptured aneurysm of the abdominal aorta in 1955 at the age of 76 years. His medical history has been well documented, and his biographies show that he was mentally adept to the end of his life.⁹ Within 7 hours of death, his brain was removed at necropsy, fresh weight was measured, perfusion of 10% formalin by injection into the internal carotid arteries was carried out, and the whole brain was then freely suspended in 10% formalin for fixation and subsequent study. No significant neuropathology was seen on examination (gross or microscopic). After fixation, caliper measurements were made directly from the brain; calibrated photographs were taken of all views of the whole brain and of the dissected hemispheres; the cerebral hemispheres were cut into approximately 240 blocks, each about 10 cm³; and the location of the blocks was recorded on photographs. The blocks were embedded in celloidin, and histological sections were made.

Lancet 1999; **353**: 2149–53

Department of Psychiatry and Behavioural Neurosciences,
McMaster University, Hamilton, Ontario, Canada (S F Witelson PhD,
D L Kigar, T Harvey MD)

Correspondence to: Dr Sandra F Witelson, Department of Psychiatry and Behavioural Neurosciences, Faculty of Health Sciences, McMaster University, HSC 3G53, 1200 Main Street West, Hamilton, Ontario L8N 3Z5, Canada (e-mail: witelson@mcmaster.ca)

Figure 1: Photographs taken in 1995 of five views of Einstein's whole brain (meninges removed)
 A, superior; B, left lateral; C, right lateral; D, inferior; E, midsagittal view of the left hemisphere. The arrow in each hemisphere indicates the posterior ascending branch of the Sylvian fissure as it runs into (is confluent with) the postcentral sulcus (compare with figure 2). Consequently, there is no parietal operculum in either hemisphere. Scale bar, 1 cm.

Although there is no record of his having made specific arrangements for post-mortem study of his brain, Einstein was sympathetic to the idea of his brain being studied. As reported in *The New York Times* in 1951, he, along with other physicists, underwent electroencephalographic recordings for research purposes.¹⁴ He also "insisted that his brain should be used for research".¹⁵ At the time of his death, the family requested a necropsy, which was done by pathologist Thomas Harvey, who took the initiative to remove the brain for scientific study. Consent was given by Einstein's elder son, Hans Albert Einstein,¹⁶ and by the executor of Einstein's estate, Prof Otto Nathan (ref 17, p 264).

Control brain specimens

The control group consisted of all the male specimens available at the time (n=35) in the Witelson Normal Brain Collection based at McMaster University. The key features of this collection are that the brains are from research volunteers with normal neurological and

psychiatric status (as judged by clinical history and medical assessments) and normal cognitive ability (as documented by research neuropsychological testing that included IQ assessment).¹⁸ In each case, informed consent with respect to testing and necropsy had been obtained. Mean Full Scale IQ score on the Wechsler Adult Intelligence Scale¹⁹ was 116 (SD 9). Quantitative measures of Einstein's brain and this control group were compared; Einstein's brain was also compared with a smaller age-matched subgroup (in the collection) of the 8 men aged 65 years or more (mean 68) for brain measures known to change with advancing age. Although women have smaller brains than men,²⁰ for purposes of descriptive analysis of gyral morphology, Einstein's brain was also compared with 56 female brains (the total number of female brains in the same collection).

Measurements

Direct caliper measurements were made both from Einstein's brain and from the control brains. Other measurements were made from calibrated photographs. We measured baseline values for overall dimensions of the brain, including variables for which there are published data (eg, weight, corpus callosum size²¹); measures involving parietal regions important for

visuospatial cognition and mathematical thinking; and, for comparison, measures of frontal and temporal regions. Statistically significant differences between Einstein and the control group were defined as those measures at least 2 SDs from the control mean.

Einstein's parietal lobes

Figure 1 shows the set of photographs taken in 1955 of the lateral, superior, inferior, and midsagittal views of Einstein's brain. The superior view (figure 1A) shows a relatively spherical brain which is corroborated quantitatively (see below). Moderate atrophy is present around the main fissures in the central regions in both hemispheres, to an extent common for a person in their eighth decade.²² A unique morphological feature is visible in the lateral surface of each hemisphere which otherwise shows usual anatomy (figure 1B, 1C)—namely, the posterior ascending branch of the Sylvian fissure is confluent with the postcentral sulcus. Consequently, there is no parietal operculum (the

anterior part of the supramarginal gyrus), which normally develops between these two sulci during fetal life.^{23,24} This morphology found in each of Einstein's hemispheres was not seen in any hemisphere of the 35 control male brains or of the 56 female brains, nor in any specimen documented in the published collections of post-mortem brains.^{25,26}

Figure 2 highlights this unique feature of Einstein's brain in comparison with a typical control brain. Three main types of morphology of the Sylvian fissure and surrounding gyri have been described previously;²⁷ in each type, the Sylvian fissure terminates or bifurcates behind the postcentral sulcus, and the parietal operculum is present. The tracing of the superimposed hemispheres of the control brain (figure 2, no 3) shows the typical right-left asymmetry in size and position of the Sylvian fissure and the parietal opercula.²⁸ By contrast, the tracing of Einstein's hemispheres (figure 2, no 6) shows the confluence of the posterior ascending branch of the Sylvian fissure and the postcentral sulcus in each hemisphere, the absence of the parietal opercula, and unusual symmetry between hemispheres of sulcal morphology in this region.

Quantitative measurements of Einstein's brain compared with the male control group are shown in the table, with relevant landmarks shown in figure 3. Einstein's brain was not statistically different from the control group on most measures. His brain weight did not differ from the control group, from the age-matched subgroup, or from published large age-matched groups (table, measure 1). Unfortunately, the volume of Einstein's brain had not been obtained. Brain length, height, size of the corpus callosum, and measures of the frontal and temporal lobes did not differ between Einstein and controls. However, size of a specific gyral region in the frontal operculum was different in Einstein's brain from that of the control group. The possible association of this feature in relation to biographical accounts of Einstein's atypical speech development¹⁷ will be reported elsewhere.

By contrast, in the parietal lobes, there were striking quantitative differences. Each hemisphere of Einstein's brain was 1 cm wider (15%) than that of the control group (measure 5). Maximum width usually occurs across the end of the Sylvian fissure—the region of unique morphology in Einstein's brain. The ratios of hemisphere width to height and of brain width to length (measures 6 and 7) showed that in Einstein's brain the parietal lobes were relatively wider and the brain more spherical (see figure 1A) than those in the control group. In Einstein's brain, the parietal operculum was missing in each hemisphere in contrast to control values of 6.1 cm² and 3.6 cm² in the left and right hemispheres,

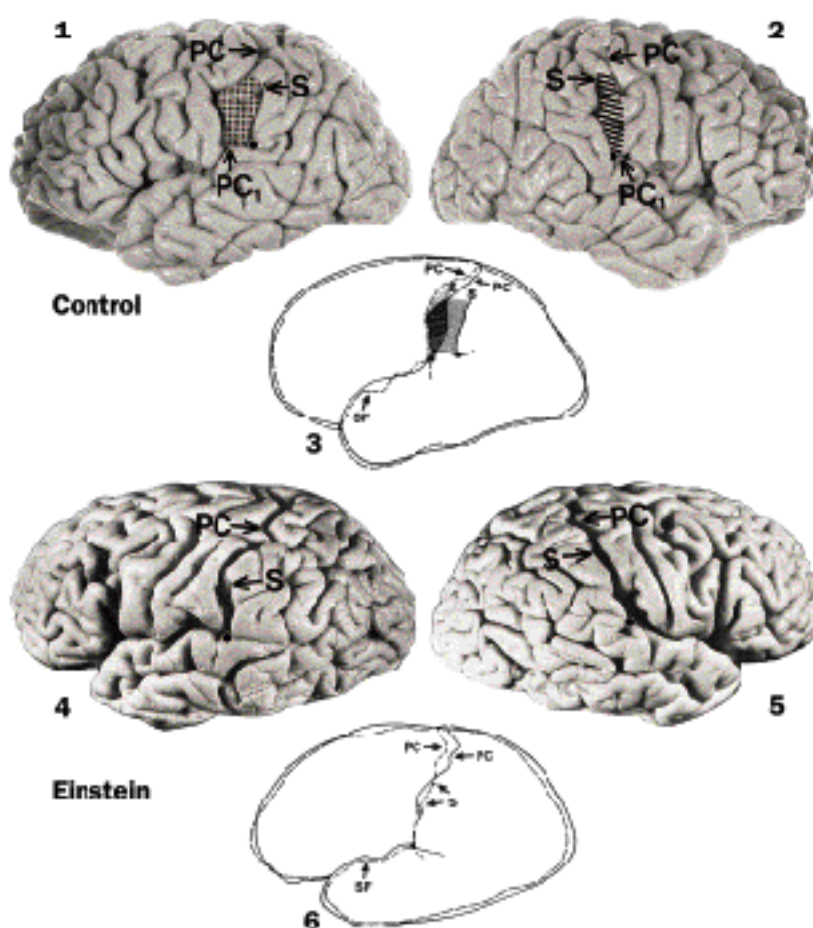


Figure 2: Lateral photographs and tracings of left (solid line) and right (dashed line) superimposed hemispheres of a typical control male brain (1, 2, 3) and the brain of Einstein (4, 5, 6)

The photographs of the control brain show the parietal operculum in the left (stippled) and right (hatched) hemisphere, situated between the postcentral (PC) sulcus and the posterior ascending branch of the Sylvian fissure (SF), which originates at the point of bifurcation (●) and terminates at S. PC₁ is the inferior end of PC at SF. The tracing of the superimposed hemispheres (3) shows the asymmetry in position and size between the parietal opercula. The tracing of Einstein's hemispheres (6) highlights the confluence of PC and the posterior ascending branch of SF in each hemisphere, the absence of the parietal opercula, and the symmetry of the sulcal morphology between hemispheres. Comparison of the tracings shows the relatively anterior position of the SF bifurcation in Einstein, and the associated greater posterior parietal expanse, particularly in his left hemisphere compared with the control brain.

respectively (measure 24). Parietal regions typically show anatomical asymmetry (table, control group, measures 19–24²⁸). Einstein's parietal lobes were symmetrical (compare with figure 2, no 6). This was due mainly to his left parietal lobe being larger than usual, resembling a right hemisphere in size and morphology.

Discussion

The gross anatomy of Einstein's brain was within normal limits with the exception of his parietal lobes. In each hemisphere, morphology of the Sylvian fissure was unique compared with 182 hemispheres from the 35 control male and 56 female brains: the posterior end of the Sylvian fissure had a relatively anterior position, associated with no parietal operculum. In this same region, Einstein's brain was 15% wider than controls. These two features suggest that, in Einstein's brain, extensive development of the posterior parietal lobes occurred early,²⁴ in both longitudinal and breadth dimensions, thereby constraining the posterior expansion

	Einstein		Control group (mean, SD)	
	Left	Right	Left	Right
Age (yr)	76		57 (11)	
Height (cm)	176		178 (8)	
Overall brain measures				
1 Brain weight, fresh (g)	1230		1400 (118)*	
2 Hemisphere weight, fixed (g)	550.0	545.0	591.0 (46.0)	591.0 (48.0)
3 Maximum height of hemisphere (cm)†	8.9	8.7	9.3 (0.6)	9.4 (0.6)
4 Length of hemisphere (OF) (cm)	17.2	16.4	16.9 (0.6)	16.8 (0.6)
5 Maximum width of hemisphere (cm)‡	7.5§	7.5§	6.5 (0.5)	6.5 (0.5)
6 Ratio of width of hemisphere to height	0.84§	0.86§	0.70 (0.07)	0.69 (0.07)
7 Ratio of width of brain to length (mean OF)	0.89§		0.77 (0.06)	
8 Corpus callosum area (cm ²)	6.8		7.0 (0.90)¶	
Frontal lobe (cm)				
9 F-PreC	9.2	9.5	9.4 (0.7)	9.2 (0.8)
10 FC	11.3	11.6	10.6 (0.6)	10.5 (0.6)
11 FA	5.1	5.1	4.8 (0.4)	4.7 (0.4)
12 A-PreC ₁	0.8	0.9	0.9 (0.4)	1.0 (0.4)
13 PreC ₁ -C ₁	1.2	1.2	1.4 (0.5)	1.2 (0.4)
Temporal lobe (cm)				
14 TO	13.2	12.8	13.2 (0.5)	13.2 (0.5)
15 C ₁ -C ₂	3.9	3.9	4.0 (0.3)	4.0 (0.3)
16 SS ₁	6.1	6.6	5.1 (1.1)	6.0 (0.9)**
Parietal/occipital lobe (cm)				
17 O-PC	8.4	7.9	8.3 (0.8)	8.4 (0.8)
18 OC	8.9	8.3	9.5 (0.6)	9.3 (0.8)
19 OB	7.1	7.9	5.8 (0.9)	7.2 (0.9)**
20 OS	8.0	7.9	6.1 (1.1)	7.4 (1.0)**
21 BS	2.5	2.9	0.9 (1.1)	2.4 (1.3)**
22 C ₁ -PC ₁	3.5§	2.0	2.3 (0.6)	2.0 (0.6)**
23 PC ₁ -B	0§	0§	1.9 (1.0)	1.1 (1.2)**
24 Parietal operculum (cm ²)	0§	0§	6.1 (3.4)	3.6 (2.1)**

Control group consists of 35 men and an age-matched male subgroup (see text).

*Our control mean of 1400 g is similar to values of other studies of large groups of white men of similar age range (30–70 years)—eg, mean fresh brain weight=1399 g, n=1433, mean age=53 years.²⁹ For the age-matched subgroup, mean (SD) fresh brain weight was 1386 g (149). In a large study, mean fresh brain weight for a 70–80 year age group was 1342 g, n=253.²⁰

†Maximum height usually occurs near the plane of point C (figure 3).

‡Maximum width of each hemisphere occurs over the end of SF (figure 3).

§Statistically different (2 SDs from the control group) or reflect unique morphology.

¶Callosal area is larger in non-right-handers and decreases with advancing age.²¹ There is evidence to suggest that Einstein was not consistently right-handed.³⁷ Einstein's callosal area of 6.8 cm² tended to be larger than his predicted value (5.9 cm²) when hand preference and age were taken into account.²¹

**Statistically significant right-left anatomical asymmetry within the control group (compare ref 28) (p<0.01, two-tailed paired t-tests).

Measurements (see figure 3) of Einstein's brain compared with a control group

of the Sylvian fissure and the development of the parietal operculum, but resulting in a larger expanse of the inferior parietal lobule. A further consequence of this morphology is that the full supramarginal gyrus lies behind the Sylvian fissure, undivided by a major sulcus as is usually the case. Van Essen²⁹ hypothesised that a gyrus develops within a region of functionally related cortex to allow for efficient axonal connectivity between opposite cortical walls of the gyrus; by contrast, sulci separate cortical regions having less functional relatedness. In this context, the compactness of Einstein's supramarginal gyrus within the inferior parietal lobule may reflect an extraordinarily large expanse of highly integrated cortex within a functional network. And in fact there is evidence that cortical representation of different functions is often separated by sulci.³⁰ This notion could be consistent with Cajal's³¹ speculation that variation in axonal connectivity may be a neuronal correlate of intelligence. A larger expanse of a functional cortical network may reflect more modules³² which could provide a functional advantage.

The inferior parietal lobule is well developed in the

Figure 3: Sketch of a typical brain showing the landmarks for defining the measurements shown in table

F, O, and T: frontal, occipital and temporal poles, respectively; PreC, C, PC: superior ends of the precentral, central and postcentral sulci, respectively; PreC₁, C₁, PC₁: inferior ends of these sulci, respectively; A, point of origin of the anterior ascending branch of the Sylvian fissure (SF); B, point of bifurcation of the posterior SF; S, end of SF; S₁, and C₂, points of the shortest distance from S and C₁, respectively, to the bottom of the temporal lobe; parietal operculum (stippled region), the anterior segment of the supramarginal gyrus which surrounds BS.

human brain; it is a secondary association area that provides for cross-modal associations among visual, somesthetic, and auditory stimuli.⁷ Visuospatial cognition, mathematical thought,¹¹ and imagery of movement¹³ are strongly dependent on this region. Einstein's exceptional intellect in these cognitive domains and his self-described mode of scientific thinking¹⁰ may be related to the atypical anatomy in his inferior parietal lobules. Increased expansion of the inferior parietal region was also noted in other physicists and mathematicians. For example, for both the mathematician, Gauss, and the physicist, Siljeström, extensive development of the inferior parietal regions, including the supramarginal gyri, was noted (ref 4, pp 180, 200).

Einstein's brain weight was not different from that of controls, clearly indicating that a large (heavy) brain is not a necessary condition for exceptional intellect.

Microscopic differences may underlie gross anatomical differences. The limited data on Einstein's brain do not point to a difference in the number of neurons throughout the depth of the cortex in the frontal or temporal lobes,^{33,34} but possibly a difference in the ratio of the number of glial cells relative to neurons in the left parietal cortex³⁵ (compare ref 36).

This report clearly does not resolve the long-standing issue of the neuroanatomical substrate of intelligence. However, the findings do suggest that variation in specific cognitive functions may be associated with the structure of the brain regions mediating those functions. The results have heuristic value for developing hypotheses of the gross and microscopic anatomical substrate of different aspects of intelligence that can be tested in future neuroimaging and post-mortem studies. In particular, the results predict that anatomical features of parietal cortex may be related to visuospatial intelligence. We also hope that this case study may be an impetus for donation of brain specimens from other gifted and normal individuals to support investigation of structure-function relations in health and disease.

This work was supported in part by US NIH contract NS62344, grant NS18954, and grant MA-10610 from MRC (Canada) to SFW. Materials were provided by the Albert Einstein Archives, The Hebrew University of Jerusalem. The contribution of the late Henry C Witelson is appreciated.

References

- 1 Deary IJ, Caryl PG. Neuroscience and human intelligence differences. *Trends Neurosci* 1997; **20**: 365–71.
- 2 Wagner R. Vorstudien zu einer wissenschaftlichen: Morphologie und Physiologie des menschlichen Gehirns als Seelenorgan. Göttingen: Verlag der Dieterichschen Buchhandlung, I 1860; II 1862.
- 3 Donaldson HH, Canavan MM. A study of the brains of three scholars. *J Comp Neurol* 1928; **46**: 1–95.
- 4 Spitzka EA. A study of the brains of six eminent scientists and scholars belonging to the American Anthropometric Society. Together with a description of the skull of Professor E D Cope. *Trans Am Philos Soc* 1907; **21**: 175–308.
- 5 Gould SJ. The mismeasure of man. New York: W W Norton, 1981.
- 6 Gardner H. Frames of mind: the theory of multiple intelligences. New York: Basic Books, 1983.
- 7 Geschwind N. Disconnexion syndromes in animals and man. *Brain* 1965; **88**: 237–97.
- 8 Wickett JC, Vernon PA, Lee DH. *In vivo* brain size, head perimeter, and intelligence in a sample of healthy adult females. *Person Individ Diff* 1994; **16**: 831–38.
- 9 Pais A. Einstein lived here. Oxford: Clarendon Press, 1994.
- 10 Einstein A. Cited in Hadamard J. The psychology of invention in the mathematical field. New Jersey: Princeton University Press, 1949:142–43.
- 11 Critchley M. The parietal lobes. New York: Hafner Publications, 1971.
- 12 Tagaris GA, Kim S, Strupp JP, Andersen P, Ugurbil K, Georgopoulos AP. Quantitative relations between parietal activation and performance in mental rotation. *Neurol Report* 1996; **7**: 773–76.
- 13 Crammond DJ. Motor imagery: never in your wildest dreams. *Trends Neurosci* 1997; **20**: 54–57.
- 14 Einstein's brainwaves being recorded: geniuses aid test of brain processes. *The New York Times*. February 24, 1951.
- 15 Clark RW. Einstein: the life and times. New York: Thomas Crowell, 1971: 630.
- 16 Brian D. Einstein: a life. New York: Wiley & Sons, 1996: 437.
- 17 Highfield R, Carter P. The private lives of Albert Einstein. New York: St Martin's Press, 1993.
- 18 Witelson SF, McCulloch PB. Premortem and postmortem measurement to study structure with function: a human brain collection. *Schizophr Bull* 1991; **17**: 583–91.
- 19 Weschler D. Manual: Weschler Adult Intelligence Scale. New York: Psychological Corporation, 1955.
- 20 Dekaban AS, Sadowsky D. Changes in brain weights during the span of human life: relation of brain weights to body heights and body weights. *Ann Neurol* 1978; **4**: 345–56.
- 21 Witelson SF. Hand and sex differences in the isthmus and genu of the human corpus callosum: a postmortem morphological study. *Brain* 1989; **112**: 799–835.
- 22 Tomlinson BE. Ageing and the dementias. In: Adams JH, Duchon LW, eds. Greenfield's neuropathology, 5th edn. London: Edward Arnold, 1992.
- 23 Chi JG, Dooling EC, Gilles FH. Gyral development of the human brain. *Ann Neurol* 1977; **1**: 86–93.
- 24 Fontes V. Morfologia do cortex cerebral (Desenvolvimento). Lisboa: Lisboa, 1944.
- 25 Connolly CJ. External morphology of the primate brain. Springfield, IL: CC Thomas, 1950.
- 26 Ono M, Kubik S, Abernathy CD. Atlas of the cerebral sulci. New York: George Thieme Verlag, 1990.
- 27 Witelson SF, Kigar DL. Sylvian fissure morphology and asymmetry in men and women: bilateral differences in relation to handedness in men. *J Comp Neurol* 1992; **323**: 326–40.
- 28 Witelson SF, Kigar DL. Asymmetry in brain function follows asymmetry in anatomical form: gross, microscopic, postmortem and imaging studies. In: Boller F, Grafman J, eds. Handbook of neuropsychology. Vol 1. Amsterdam: Elsevier Science, 1988.
- 29 Van Essen DC. A tension-based theory of morphogenesis and compact wiring in the central nervous system. *Nature* 1997; **385**: 313–18.
- 30 Welker WI, Campos GB. Physiological significance of sulci in somatic sensory cerebral cortex in mammals of the family *Procyonidae*. *J Comp Neurol* 1963; **120**: 19–36.
- 31 Cajal S. Recollections of my life. London: MIT Press, 1989.
- 32 Stevens CF. How cortical interconnectedness varies with network size. *Neural Computation* 1989; **1**: 473–79.
- 33 Anderson B, Harvey T. Alterations in cortical thickness and neuronal density in the frontal cortex of Albert Einstein. *Neurosci Lett* 1996; **210**: 161–64.
- 34 Kigar DL, Witelson SF, Glezer IL, Harvey T. Estimates of cell number in temporal neocortex in the brain of Albert Einstein. *Soc Neurosci Abstr* 1997; **23**: no 89.9.
- 35 Diamond MC, Scheibel AB, Murphy JGM, Harvey T. On the brain of a scientist: Albert Einstein. *Exp Neurol* 1985; **88**: 198–204.
- 36 Hines T. Further on Einstein's brain. *Exp Neurol* 1998; **150**: 343–44.
- 37 Winokur M. Einstein: a portrait. Corte Madera, CA: Pomegranate Artbooks, 1984.